

Effect of *Cnidoscolus aconitifolius* Extract on Rat Liver Injury Induced with Carbon Tetrachloride (CCl₄)

by Zamharira Muslim

Submission date: 14-Mar-2023 02:51PM (UTC+0700)

Submission ID: 2036877068

File name: 2022-12-TJNPR-2022-Zamharira_Muslim.pdf (305.59K)

Word count: 4688

Character count: 25320

**Effect of *Cnidoscolus aconitifolius* Extract on Rat Liver Injury Induced with Carbon Tetrachloride (CCl₄)**Zamharira Muslim^{1*}, Jon Farizal², Rahmad Abdillah³, Sunita Sunita²¹Department of Pharmacy, Poltekkes Kemenkes Bengkulu, Bengkulu, Indonesia²Department of Technology Laboratorium Medic, Poltekkes Kemenkes Bengkulu, Bengkulu, Indonesia³Department of Pharmacology, Faculty of Pharmacy, Universitas Andalas, Padang, Indonesia

ARTICLE INFO

Article history:

Received 26 October 2022

Revised 10 November 2022

Accepted 11 November 2022

Published online 01 December 2022

Copyright: © 2022 Muslim *et al.* This is an open-access article distributed under the terms of the [Creative Commons Attribution License](https://creativecommons.org/licenses/by/4.0/), which permits unrestricted use, distribution, and reproduction in any medium, provided the original author and source are credited.

ABSTRACT

Cnidoscolus aconitifolius in Indonesia is consumed as a vegetable which contains phenolic compounds known to have activity in the liver. This study was designed to determine the hepatoprotective effect of various doses of *C. aconitifolius* extract on the liver of rats injury induced with carbon tetrachloride (CCl₄). Thirty-six Wistar rats were used in this study, divided into six groups. Normal group, positive control, negative control, and treatment groups of *C. aconitifolius* extract (50, 100, and 200 mg/kg). The study analysed serum transaminases and liver histopathology of rats. Serum analysis was performed to determine the activity of aspartate aminotransferase (AST), alanine aminotransferase (ALT), total cholesterol, and albumin levels. The histopathology of rat liver was analyzed using the Mandja Roenigk method. This study showed that in the groups treated with *C. aconitifolius* extract at the doses of 50 mg/kg, 100 mg/kg and 200 mg/kg (Group D, E, F) respectively, there was a decrease in ALT, AST and cholesterol levels. In contrast, albumin levels increased compared to the positive control (Group B) (p<0.05). The administration of *C. aconitifolius* extract (Group F: 200 mg/kg b.w) had almost the same effect as the administration of Curcuma Force® (Group C) (P>0.05). This study showed improvement in the liver function of rats after administration of *C. aconitifolius* extract. In conclusion, *C. aconitifolius* possesses a hepatoprotective effect on rat liver damage caused by CCl₄ induction.

Keywords: *Cnidoscolus aconitifolius*, Hepatoprotective, Liver, Carbon tetrachloride.

Introduction

Liver damage is common in patients who use synthetic drugs continuously.¹ This can happen because the liver metabolizes most drugs which can reduce liver function. The use of natural materials is an alternative choice for solving these problems. Various types of plants have long been used in traditional medicine. Currently, many studies use plant samples to find the activity of active molecules that can be used as drug candidates in the future.² *Cnidoscolus aconitifolius* belongs to the group of arborescent shrubs. This plant can grow up to 6 meters, the leaves are lobed palmately green, and have small flowers in dichotomous branched cymes and milky sap. *C. aconitifolius* is often used as food, medicine, and ornamental plant until now.³ *C. aconitifolius* has several pharmacological effects such as hypoglycemic⁴, antibacterial¹, antioxidant⁵, analgesic and anti-inflammatory⁶, treatment of high-dose paracetamol poisoning⁷, and hepatoprotective.⁸ This plant was first cultivated as a vegetable in the regions of Southeastern Mexico and Maya Guatemala.⁹ Due to the easy cultivation process, the plant has spread throughout the world including the tropics. Indonesia as a tropical country has many types of plants that can be developed into treatment options. *C. aconitifolius* is a type of plant that grows well in Indonesia and it is still a prospect to observe its effects on human health further. Indonesian people often call it Japanese Papaya and are usually only used as a vegetable food ingredient.

*Corresponding author. E mail: zamharira@poltekkesbengkulu.ac.id
Tel: +6285263634060

Citation: Muslim Z, Farizal J, Abdillah R, Sunita S. Effect of *Cnidoscolus aconitifolius* Extract on Rat Liver Injury Induced with Carbon Tetrachloride (CCl₄). Trop J Nat Prod Res. 2022; 6(11):1809-1813. <http://www.doi.org/10.26538/tjnpr/v6i11.11>

Official Journal of Natural Product Research Group, Faculty of Pharmacy, University of Benin, Benin City, Nigeria.

C. aconitifolius in Nigeria is known as Chaya and is usually consumed in Yoruba-land, Nigeria as a vegetable.¹⁰ *C. aconitifolius* leaves contain Tannins, Saponins, Alkaloids, Flavonoids, Cyanogenic Glycosides, and Phytates.¹¹ These benefits mainly come from the phenolic compounds it contains. The results of research on the therapeutic effect of *C. aconitifolius* as a hepatoprotector are still very limited, especially regarding variations in dose and liver function parameters of rats induced by carbon tetrachloride (CCl₄). The liver enzyme alanine transaminase (ALT), aspartate transaminase (AST), alkaline phosphatase (APT), albumin (Alb), total bilirubin, and total protein (TP) are biomarkers that can be observed to estimate the extent of hepatocyte damage.¹² This study aim to determine the hepatoprotective effect of extract of *C. aconitifolius* on CCl₄-induced rat liver function.

Materials and Methods

Plant Materials

C. aconitifolius was collected from Bengkulu Province, Indonesia. *C. aconitifolius* was identified in the Biology Herbarium, Faculty of Mathematics and Natural Sciences, Bengkulu University, with certificate number 525/UN30.12.LAB.BIOLOGI/KM/2021.

Extraction *C. aconitifolius*

C. aconitifolius leaves began with the selection of samples with the criteria of plants being more than one year old and choosing leaves that are not too old. Leaf samples collected were approximately 5 kg, dried to a moisture content of 6.41% and mashed. The extraction process was carried out at the Biota Sumatra Laboratory, Andalas University. A dried sample (500 g) was extracted by maceration method using 5 litre 70% ethanol. After the maceration process was completed, the filtrate was evaporated using a Rotary Evaporator (Buchi® R210), and 8 g of thick extract was obtained.

The extraction process was carried out according to the standards of the Indonesian Herbal Pharmacopoeia Edition 2.¹³

Animals and experimental design

This study used male Wistar rats. The weight of the animals was 200-250 g. The study protocols were approved by the Health Research Ethics Commission of the Bengkulu Ministry of Health Poltekkes; the approval number KEPK/114/04/2022. The animal study was carried out at the Animal House, Faculty of Pharmacy at Andalas University. Rats were placed in separate cages for two weeks for acclimatization under laboratory conditions (humidity 50% ± 10%, temperature 27°C ± 3°C and under 12 h light - 12 h dark periods). Animals receive adequate food and drink according to standard procedures based on the Guide for the Care and Use of Laboratory Animals. All activities are carried out by minimizing animal pain and using animals as efficiently as possible.

Experimental Design

Experimental animals were divided into six groups that received intervention for two weeks. Each group consisted of 6 rats. Table 1 describes the groups of treatment in detail. All groups in this study were induced with CCL₄ (1.25 mL/kg) as a hepatotoxic agent obtained from the Laboratory of the Faculty of Pharmacy, Andalas University, except group A as normal control. Curcuma Force[®] (4 mg/kg) contains *Curcuma xanthorrhizae* and *Piperis nigris* produced by SOHO Pharmaceutical Industry as a positive control. The various doses of the *C. aconitifolius* extract used were 50 mg/kg; 100 mg/kg; and 200 mg/kg. CCL₄ (1.25 mL/kg) was administered via the intraperitoneal route while the natrium carboxymethylcellulosa (CMC Na) suspension and extract were administered orally.

Blood Sample Collection and Analysis

After the intervention for two weeks, blood was collected through the rat eye arteries as much as 5 mL using an EDTA tube. Rat blood analysis was performed using a Hematology Analyzer with DiaSys[®] reagents. Then the animal was sacrificed by cervical dislocation. Before the animals were sacrificed, Ketamine (40 mg/kg b.w) and Xylazine (5 mg/kg b.w) were administered intraperitoneally as anaesthetics and analgesics.

Histological Analysis

Livers of the rats were collected after the animals were sacrificed by cervical dislocation. Before sectioning, the liver was fixed in a 10% buffered formalin solution for 24 hours. The liver tissue was dehydrated in 70%, 80%, 90%, and 96% alcohol, xylol, and liquid paraffin, in that order. The following stages are tissue vacuuming and embedding. The liver tissue was sectioned and stained with hematoxylin and eosin at a thickness of 4-6 mm. Histological findings of the liver included central veins, hepatocytes, hepatocyte cell arrangement, and pathological liver abnormalities such as parenchymal degeneration, hydropic degeneration, and necrosis of liver hepatocytes. A 40-times magnification microscope with Olympus CX33[®] was used to examine liver tissue in five distinct fields of view. The average stained area and staining intensity of the five fields were chosen.

Table 1: Experimental groups

Groups	Treatment
A	CMC Na 1%
B	CMC Na 1% + CCL ₄ *
C	CMC Na 1% + CCL ₄ * + Curcuma Force [®] *
D	CCL ₄ * + CMC Na 1% + 50mg/kg b.w extract of <i>C. aconitifolius</i>
E	CCL ₄ * + CMC Na 1% + 100mg/kg b.w extract of <i>C. aconitifolius</i>
F	CCL ₄ * + CMC Na 1% + 200mg/kg b.w extract of <i>C. aconitifolius</i>

* CCL₄ doses: 1.25 mL/kg b.w

* Curcuma Force[®] doses: 4mg/kg b.w

A semi-quantitative histopathology score modified from the recently recognised Manja-Roegnik criteria was used to assess the histopathological characteristics of liver damage.

Statistical analysis

AST, ALT, Albumin and Total Cholesterol examination data were analyzed by the one-way ANOVA method using SPSS[®] software. Statistical analysis obtained the mean, standard deviation (SD) and P-Value. P-values at p<0.05 were considered significant.

Results and Discussion

Effect of *C. aconitifolius* on rat liver function parameters

This study evaluated the effect of *C. aconitifolius* extract on CCL₄-induced rat liver damage. Liver cell damage can be caused by various factors such as autoimmune disease, bacteria, viruses, and parasites, the influence of chemicals, such as some drugs (high doses of paracetamol and antituberculosis drugs), toxic compounds (thioacetamide and carbon tetrachloride (CCl₄)).¹⁴ Research has led to the use of plants that have hepatoprotective effects. However, no substance is fully effective in providing complete protection to the liver, or helping to regenerate liver cells.¹⁵

The results of serum examination in group B showed damage to the liver cells of rats. These results were indicated by a decrease in serum albumin levels compared to other treatment groups, while total cholesterol levels and AST and ALT activities increased (Table 2). In group C administered Curcuma force[®] to rats and liver damage induced with CCL₄, the results show a decrease in AST, ALT, and total cholesterol. At the same time, albumin levels were slightly increased compared to group B (p<0.05) (Table 2).

The findings in this study showed that there was liver damage caused by CCL₄ based on serum assays and histopathological analysis. Previous studies that used CCL₄ as an inducer of liver damage in experimental studies using animals, proved successful in damaging liver cells at a dose of 1.25 mL/kg b.w. CCL₄ damages liver cells by activating enzymes such as CYP2E1, CYP2B1 or CYP2B2 and possibly CYP3A, which reduce CCL₄ to CCL₃, which is a free radical.¹⁶ CCL₃ causes oxidative stress in liver cells, thereby increasing the activity of transaminase enzymes and the formation of steatosis.¹⁷ CCL₄ was also reported to reduce albumin levels in rats induced for ten weeks.¹⁸ CCL₄ induction can increase the synthesis of fatty acids, triglycerides and cholesterol.¹⁹ Based on the ability of CCL₄ to damage liver cells, CCL₄ was used as a negative control in this study.

Curcuma is one of the natural ingredients that is well known as a hepatoprotective.²⁰ Previous studies reported that piperine is a potent inhibitor of CYP450 enzymes, particularly CYP3A4, CYP2C9, and CYP1A2.²¹ CYPs also function in the biosynthesis of steroids, lipids, and other secondary metabolites.²² In this study, we used Curcuma Force[®] containing *Curcuma xanthorrhizae* and *Piperis nigris* as positive controls. Decreased activity of the enzyme transaminase indicates that liver cells are undergoing repair. The increase in albumin levels to reach the normal range of albumin levels in rats also occurred in group C, which was treated with Curcuma Force[®]. Increased albumin levels are one sign of improvement in rat liver cells. The liver is an organ that functions for albumin synthesis.²³ Other studies suggest that Curcuma has the effect of lowering serum levels of lipid peroxides and total cholesterol.²⁴

The results in groups D, E, and F showed that the activity of AST, ALT, and total cholesterol levels decreased. At the same time, albumin increased after administration of extract of *C. aconitifolius* (Table 2). The decreased activity was significant in AST and ALT (p<0.000), total cholesterol (p<0.001) and an increase in albumin (p<0.002). These results are linear with variations in the dose of *C. aconitifolius* extract. The higher the dose of *C. aconitifolius*, the better the hepatoprotective effect. Some research results state that *C. aconitifolius* contains phenolic compounds such as Hesperidin,²⁵ Kaempferol,²⁶ Lignin,^{25,26} Protocatechic acid,^{25,29} Quercetin,³⁰ Rutine,^{27,28} Triterpenes, glycosides, phenolic compounds, and flavonoids as classes of compounds with hepatoprotective activity.³¹ This study showed that *C. aconitifolius* ethanol extract had a good effect on the repair of rat liver cells damaged by CCL₄.

Table 2: AST, ALT, albumin and total cholesterol value post-treatment by extract of *C. aconitifolius*.

Groups	AST (U/L)*	ALT (U/L)*	Albumin (g/dL)**	Total Cholesterol (mg/dL)***
A	15.58 ± 1.63	19.26 ± 1.32	5.6 ± 0.10	59.78 ± 5.13
B	27.63 ± 6.87 ^c	32.48 ± 2.10 ^c	5.12 ± 0.16 ^c	73.61 ± 6.59 ^c
C	19.95 ± 3.18 ^d	24.3 ± 1.34 ^d	5.17 ± 0.28	59.66 ± 5.89 ^d
D	25.75 ± 1.53 ^b	31.35 ± 0.98	5.11 ± 0.33 ^b	65.83 ± 6.80 ^b
E	23.61 ± 2.2 ^b	25.8 ± 1.59 ^{ab}	5.39 ± 0.38 ^b	65.2 ± 2.76 ^b
F	19.8 ± 0.99 ^{ab}	24.6 ± 1.31 ^{ab}	5.48 ± 0.31 ^b	61.5 ± 4.34 ^{ab}

Values are presented as Mean ± SD. There are 6 animals in each group (n=6). $P < 0.005$ value are considered statically significant. Asterisk * $P < 0.000$; ** $P < 0.002$; *** $P < 0.001$. ^a indicates value is significantly different at $P < 0.05$ vs group B. ^b indicates value is not significantly different at $P > 0.05$ vs group C. ^c indicates value is not significantly different at $P > 0.05$ vs group A. ^d indicates value is significantly different at $P > 0.05$ vs group B. Statistical test between groups using one-way ANOVA and a Tukey's post hoc multiple comparison test.

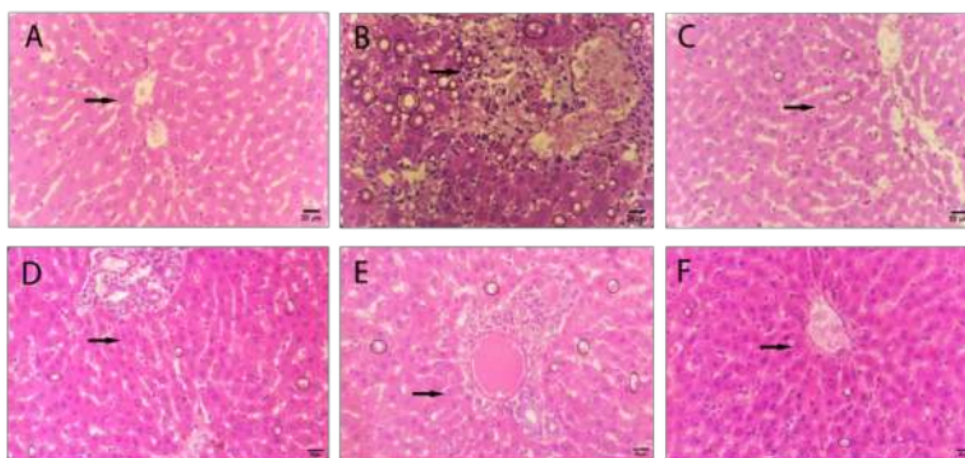


Figure 1: Representative histopathological rat liver with magnification 400X. A (Group A: Normal Control) showed normal liver cells (arrows); B (Group B: Negative Control) showed the occurrence of necrosis (arrows) and steatosis (circles); C (Group C: Positive Control) showed that there were cell repairs in the form of parenchymal degeneration (arrows) to normal and steatosis (circles); D (Group D: Treatment 50 mg/kg b.w extract of *C. aconitifolius*) and E (Group E: 100 mg/kg b.w extract of *C. aconitifolius*) showed necrosis to hydrophilic degeneration (arrows) and (circles); F (Group F: 200 mg/kg b.w extract of *C. aconitifolius*) showed cell recovery (arrows) and reduced steatosis.

Table 3: Analysis Mandja Roenigk's histopatology score

Group*	Score**	p-Value***
A	1 ± 0.00	
B	4 ± 0.00	
C	3 ± 0.75	0.011
D	3.77 ± 0.33	
E	3.56 ± 0.24	
F	3.3 ± 0.73	

*Each group 5 repetition

**Score are Mean ± SD.

The higher the dose of *C. aconitifolius*, the more significant the improvement in liver cell condition based on serum and histopathological examinations.

The results of enzyme activity; AST, ALT, and total cholesterol levels appeared to decrease. In contrast, albumin levels increased in groups D, E, and F. This condition explained a significant difference compared to group B as a negative control ($p < 0.05$), but there was no significant difference. A significant difference with group C as a positive control ($p > 0.05$). Damage to hepatocytes, causing the release

of ALT and AST in the cytoplasm or mitochondria into the blood circulation. The ALT enzyme is located mainly in the hepatocyte cytosol. Meanwhile, AST enzymes are found not only in liver cells but in cells in other organs, such as the heart, kidneys, and pancreas. Increased ALT and AST activity is a sign of liver cell damage.³² In conditions of acute liver injury, ALT increased more significantly than AST.³³

Effect of *C. aconitifolius* on histopathology of rat liver

Based on the histological observations of group B (Figure 1.B), necrosis of hepatocytes (arrows in Figure 1.B) and steatosis (circles in Figure 1.B) were seen. The results of Mandja Roenigk scoring of the histological samples in group B showed an average score of 4 (Table 3). The interpretation of Score 4 is that many cells undergo necrosis. Meanwhile, histopathological observations in group C showed improvement in liver cells to normal again (arrows in Figure 1.C), and steatosis appeared to be significantly reduced. The histopathological observation of rat liver (Figure 1. D, E, F) also showed improvement of liver cells with reduced necrosis starting from low doses (Group D) to normal hepatocytes seen at the highest dose of an extract of *C. aconitifolius* (Group F) and reduced steatosis. The higher the extract dose of *C. aconitifolius*, the better the liver condition of the rats in this study. Mandja Roenigk scoring in groups C, D, E, and F showed improvement with a score of 3 (hydropic degeneration) (Table 3).

Based on the scoring given to each group, there was a significant difference between group B as a negative control and the other groups ($p < 0.05$). Hepatocyte damage can be in the form of necrosis, parenchymal necrosis, inflammation, atypia, degeneration, hepatocyte pleomorphism, ductal proliferation, cytoplasmic eosinophilia, and inflammatory cells in the portal area.³⁴ Histopathological liver damage can occur in reversible and irreversible forms. Reversible cell damage can be observed through microscopic examination in the form of cell swelling (hydropic degeneration) and fatness (steatosis).²³ In this study, we looked at the condition of rat liver cells through histopathological examination induced by CCl_4 , Curcuma Force[®], and treated with *C. aconitifolius*.

Histopathological observations in this study used the Mandja Roenigk scoring. Normal cells were given a score of 1 point, cells with parenchymatous degeneration were given a score of 2 points, cells with hydropic degeneration were given a score of 3 points, and necrotic cells were given a score of 4 points.³⁵ Based on histopathological observations, Group A showed normal liver cell shape because it was only treated with 1% Na CMC (Figure 1.A). The average score of Group A is 1 and can be interpreted as a normal hepatocyte condition. Microscopic observation of the liver specimens of Group B rats showed necrosis of hepatocytes and steatosis (Figure 1.B). Steatosis occurs due to the effect of CCl_4 , which has been reduced by Cytochrome P450 (CYP) enzymes.³⁶ Based on the results of microscopic observations, the average score of Group B was 4 (Table 4). So it can be interpreted that most hepatocytes in Group B are necrotic. The histopathological condition of steatosis decreased in Groups D, E and F, which was confirmed by a downward trend in the average total cholesterol level compared to the other groups (Table 2). The average score of hepatocyte condition in the group given the extract of *C. aconitifolius* was at a score of 3 (hydropic degeneration). Based on this, it can be seen that there is an improvement in the condition of the liver cells of rats given *C. aconitifolius* compared to the normal and negative control groups, while when compared to the group given Curcuma Force[®], the improvement is the same with an average score of 3.

Conclusion

Based on the results of serum analysis and confirmation of histopathological examination of the liver of rats showed that *C. aconitifolius* had a hepatoprotective effect. At a dose of 200mg/kg b.w, the hepatoprotective effect of the extract was comparable to the hepatoprotective effect of the positive control.

1

Conflict of Interest

The authors declare no conflict of interest.

Authors' Declaration

The authors hereby declare that the work presented in this article is original and that any liability for claims relating to the content of this article will be borne by them.

Acknowledgements

The authors thank the Ministry of Health Republic of Indonesia for financial support. Faculty of Pharmacy, Universitas Andalas, and Balai Veteriner Bukit Tinggi, Indonesia for their technical assistance and support during this research.

References

- Singh A, Joshi S, Joshi A, Patni P, Tewari D. Chapter 8 - Drug-induced hepatotoxicity. In: Alavian SM, Nabavi SM, Nabavi SF, Silva Bioactive Compounds, and Plant Extracts in Liver Diseases ASBTI of N, eds. Influence of Nutrients, Bioactive Compounds, and Plant Extracts in Liver Diseases. Academic Press; 2021; 141-157.
- Saha P, Talukdar AD, Nath R, Sarker SD, Nahar L, Sahu J and Choudhury MD. Role of natural phenolics in hepatoprotection: A mechanistic review and analysis of regulatory network of associated genes. Front Pharmacol. 2019; 10(MAY):1-25.
- Awoyinka OA, Balogun IO, Ogunmowo AA. Phytochemical screening and in vitro bioactivity of *Cnidioscolus aconitifolius* (Euphorbiaceae). J Med Plants Res. 2007; 1(3):63-65.
- Figueroa-Valverde L, Díaz-Cedillo F, Camacho-Luis A, Ramos ML. Efectos inducidos por *Ruta graveolens* L., *Cnidioscolus chayamansa* McVaugh y *Citrus aurantium* L. sobre los niveles de glucosa, colesterol y triacilglicéridos en un modelo de rata diabética. Rev Bras Farmacogn. 2009; 19(4):898-907.
- Miranda-Velasquez L, Oranday-Cardenas A, Lozano-Garza H, Rivas-Morales C, Chamorro-Cevallos G, Cruz-Vega DE. Hypocholesterolemic Activity from the Leaf Extracts of *Cnidioscolus chayamansa*. Plant Foods Hum Nutr. 2010; 65(4):392-395.
- Onasanwo SA, Oyagbemi AA, Saba AB. Anti-inflammatory and analgesic properties of the ethanolic extract of *Cnidioscolus aconitifolius* in rats and mice. J Basic Clin Physiol Pharmacol. 2011;22(1-2):34-41.
- Oyagbemi AA and Odetola AA. Hepatoprotective effects of ethanolic extract of *Cnidioscolus aconitifolius* on paracetamol-induced hepatic damage in rats. Pakistan J Biol Sci. 2010; 13(4):164-169.
- Oyagbemi AA and Odetola AA. Hepatoprotective and nephroprotective effects of *Cnidioscolus aconitifolius* in protein energy malnutrition induced liver and kidney damage. Pharmacognosy Res. 2013;5(4):260-264.
- Ross-ibarra J and Molina-cruz A. The ethnobotany of *chaya* (*Cnidioscolus aconitifolius* ssp. *aconitifolius* breckon): Econ Bot. 2002; 56(4):350-365.
- Somade OT, Ugbaja RN, Idowu MA, Akinloye OA. *Cnidioscolus aconitifolius* leaf extract and ascorbate confer amelioration and protection against dimethyl nitrosamine-induced renal toxicity and testicular abnormalities in rats. Toxicol Reports. 2021; 8(April):1098-1108.
- Obichi E, Monago C, Belonwu D. Effect of *Cnidioscolus aconitifolius* (Family Euphorbiaceae) Aqueous Leaf Extract on Some Antioxidant Enzymes and Haematological Parameters of High Fat Diet and Streptozotocin Induced Diabetic Wistar Albino Rats. J Appl Sci Environ Manag. 2015; 19(2):201.
- Ali SA, Sharief NH, Mohamed YS. Hepatoprotective Activity of Some Medicinal Plants in Sudan. Evidence-based Complement Altern Med. Published online 2019.
- Direktur Jenderal Bina Kefarmasian dan Alat Kesehatan. Farmakope Herbal Indonesia. IL; 2017.
- Madrigal-Santillán, E., Madrigal-Bujaidar, E., Álvarez-González, I., Sumaya-Martínez, M. T., Gutiérrez-Salinas, J., Bautista, M., Morales-González, Á., García-Luna y González-Rubio, M., Aguilar-Faisal, J. L., & Morales-González, J. A. Review of natural products with hepatoprotective effects. World J Gastroenterol. 2014; 20(40):14787-14804.
- Chattopadhyay RR. Possible mechanism of hepatoprotective activity of *Azadirachta indica* leaf extract: Part II. J Ethnopharmacol. 2003; 89:217-219.
- Weber LWD, Boll M, Stampfl A. Hepatotoxicity and mechanism of action of haloalkanes: Carbon tetrachloride as a toxicological model. Crit Rev Toxicol. 2003;33(2):105-136.
- Slater TF. Free-radical mechanisms in tissue injury. Biochem J. 1984; 222(1):1-15.
- Natsume M, Tsuji H, Harada A, Akiyama M, Yano T, Ishikura H, Nakanishi I, Matsushima K, Kaneko S, Mukaida N. Attenuated liver fibrosis and depressed serum albumin levels in carbon tetrachloride-treated IL-6-deficient mice. J Leukoc Biol. 1999; 66(4):601-608.
- Boll M, Weber LWD, Becker E, Stampfl A. Pathogenesis of Carbon Tetrachloride-Induced Hepatocyte Injury Bioactivation of CCl_4 by Cytochrome P450 and Effects on Lipid Homeostasis. Zeitschrift für Naturforsch - Sect C J Biosci. 2001; 56(1-2):111-121.
- Farkhondeh T and Samarghandian S. The hepatoprotective

- effects of curcumin against drugs and toxic agents: an updated review. *Toxin Rev.* 2016; 35(3-4):133-140.
21. Bhardwaj RK, Glaeser H, Becquemont L, Klotz U, Gupta SK, Fromm MF. Piperine, a major constituent of black pepper, inhibits human P-glycoprotein and CYP3A4. *J Pharmacol Exp Ther.* 2002; 302(2):645-650.
 22. Tsukamoto S, Cha BC, Ohta T. Dipiperamides A, B, and C: Bisalkaloids from the white pepper *Piper nigrum* inhibiting CYP3A4 activity. *Tetrahedron.* 2002;58(9):1667-1671.
 23. Maulina M. Zat-Zat Yang Mempengaruhi Histopatologi Hepar. Unimal Press; 2018.
 24. Soni KB and Kuttan R. Effect of oral curcumin administration on serum peroxides and cholesterol levels in human volunteers. *Indian J Physiol Pharmacol.* 1992; 36(4):273-275.
 25. Ramos-Gomez M, Figueroa-Pérez MG, Guzman-Maldonado H, Loarca-Piña G, Mendoza S, Quezada-Tristán T and Reynoso-Camacho R. Phytochemical Profile, Antioxidant Properties and Hypoglycemic Effect of Chaya (*Cnidoscolus Chayamansa*) in STZ-Induced Diabetic Rats. *J Food Biochem.* 2017; 41(1):1-9.
 26. Kuti JO and Konuru HB. Antioxidant Capacity and Phenolic Content in Leaf Extracts of Tree Spinach (*Cnidoscolus* spp.). *J Agric Food Chem.* 2004; 52(1):117-121.
 27. Numa S, Rodríguez L, Rodríguez D, Coy-Barrera E. Susceptibility of *Tetranychus urticae* Koch to an ethanol extract of *Cnidoscolus aconitifolius* leaves under laboratory conditions. *Springerplus.* 2015; 4(1).
 28. Sarmiento-Franco L, Sandoval-Castro CA, McNab JM, Quijano-Cervera R, Reyes-Ramirez RR. Effect of age of regrowth on chemical composition of chaya (*Cnidoscolus aconitifolius*) leaves. *J Sci Food Agric.* 2003; 83(6):609-612.
 29. Loarca-Piña G, Mendoza S, Ramos-Gómez M, Reynoso R. Antioxidant, Antimutagenic, and Antidiabetic Activities of Edible Leaves from *Cnidoscolus chayamansa* Mc. Vaugh. *J Food Sci.* 2010; 75(2):68-72.
 30. Valenzuela Soto, Ramón, Morales Rubio, María Eufemia, Verde Star, María Julia, Oranday Cárdenas, Azucena, Preciado-Rangel, Pablo, Antonio González, Jacob, & Esparza-Rivera, Juan Ramón. *Cnidoscolus chayamansa* hidropónica orgánica y su capacidad hipoglucemiante, calidad nutraceutica y toxicidad. *Rev Mex Ciencias Agrícolas.* 2017; 6(4):815.
 31. Adewusi EA and Afolayan AJ. A review of natural products with hepatoprotective activity. *J Med Plants Res.* 2010; 4(13):1318-1334.
 32. Husna F, Arozal W, Yusuf H, Safaranti S. Protective effect of mangiferin on doxorubicin-induced liver damage in animal model. *J Res Pharm.* 2022; 26(1):44-51.
 33. Začiragić Asija, Višnja Muzika, Amina Valjevac, Amela Dervišević, Maja Mitrašnović-Brulić, Muhamed Fočak, Esad Čosović, Selma Aličelebić, Samra Čustović, And Damir Suljević. 2019. The protective effects of vitamin D3 on histopathology of pancreas and liver in streptozotocin-induced diabetic rats. *J Res Pharm.* 2022; 26(2):325-333.
 34. Yagmurca M, Bas O, Mollaoglu H, Sahin O, Nacar A, Karaman O, Songur A. Protective Effects of Erdosteine on Doxorubicin-induced Hepatotoxicity in Rats. *Arch Med Res.* 2007; 38(4):380-385.
 35. Ross Michael H, Kaye Gordon I, Wojciech P. *Histology a text and atlas.* Published online 2003.
 36. Zheng YP, Zhong XY, Huang YS, Zheng C Bin. HCBP6 is involved in the development of hepatic steatosis induced by high-fat diet and CCL₄ in rats. *Ann Hepatol.* 2018; 17(3):511-518.

Effect of *Cnidioscolus aconitifolius* Extract on Rat Liver Injury Induced with Carbon Tetrachloride (CCl₄)

ORIGINALITY REPORT

19%

SIMILARITY INDEX

13%

INTERNET SOURCES

16%

PUBLICATIONS

6%

STUDENT PAPERS

PRIMARY SOURCES

- 1 Peter O. Osarumwense. "Analgesic activity of newly synthesized 7-chloro-2-methyl-4H-benzo[d][1,3]-oxazin-4-one and 3-amino-7-chloro-2-methyl-quinazolin-4(3H)-one", *Ovidius University Annals of Chemistry*, 2018
Publication 1%
- 2 www.agrifoodscience.org
Internet Source 1%
- 3 www.longdom.org
Internet Source 1%
- 4 Mengya Xia, Gregory M. Fosco, Bethany C. Bray, John H. Grych. "Constellations of family closeness and adolescent friendship quality", *Family Relations*, 2021
Publication 1%
- 5 Oluwatobi T. Somade, Regina N. Ugbaja, Mopelola A. Idowu, Oluseyi A. Akinloye. "Cnidioscolus aconitifolius leaf extract and ascorbate confer amelioration and protection against dimethyl nitrosamine-induced renal

toxicity and testicular abnormalities in rats",
Toxicology Reports, 2021

Publication

6	test.dovepress.com Internet Source	<1 %
7	ftp.academicjournals.org Internet Source	<1 %
8	www.wjgnet.com Internet Source	<1 %
9	Oyagbemi, A A, Odetola, A A, Azeez, I O. "Ameliorative effects of Cnidocolus aconitifolius on anaemia and osmotic fragility induced by protein-energy malnutrition", African Journal of Biotechnology, 2008 Publication	<1 %
10	Submitted to Universitas Katolik Widya Mandala Student Paper	<1 %
11	phcogj.com Internet Source	<1 %
12	C. G. Pontrello, M.-Y. Sun, A. Lin, T. A. Fiacco, K. A. DeFea, I. M. Ethell. "Cofilin under control of -arrestin-2 in NMDA-dependent dendritic spine plasticity, long-term depression (LTD), and learning", Proceedings of the National Academy of Sciences, 2012 Publication	<1 %

13	eijppr.com Internet Source	<1 %
14	www.ajol.info Internet Source	<1 %
15	www.ijhcum.net Internet Source	<1 %
16	William Echavidre, Jerome Durivault, Celia Gotorbe, Thays Blanchard et al. "Integrin-alpha V beta 3 is a fundamental factor in medulloblastoma tumorigenicity and radioresistance: A new game for an old player", Cold Spring Harbor Laboratory, 2023 Publication	<1 %
17	faculty.gvsu.edu Internet Source	<1 %
18	ijns.sums.ac.ir Internet Source	<1 %
19	mdpi-res.com Internet Source	<1 %
20	pubmed.ncbi.nlm.nih.gov Internet Source	<1 %
21	www.repository.cam.ac.uk Internet Source	<1 %
22	www.sanamed.rs Internet Source	<1 %

23

Ilango, K, and V Chitra. "Hepatoprotective and antioxidant activities of fruit pulp of limonia acidissima linn", International Journal of Health Research, 2010.

Publication

<1 %

24

Maedeh Rafiee, Pejman Mortazavi, Ahmad Asghari. "Evaluation of Plantago ovata ethanolic extract on histopathological, immunohistochemical and biochemical indexes in the liver of BDL-induced cholestatic rats", Research Square Platform LLC, 2022

Publication

<1 %

25

Sachiko Tsukamoto, Bae-Cheon Cha, Tomihisa Ohta. "Dipiperamides A, B, and C: bisalkaloids from the white pepper Piper nigrum inhibiting CYP3A4 activity", Tetrahedron, 2002

Publication

<1 %

26

Ya-Ling Hou, Ya-Hui Tsai, Yun-Ho Lin, Jane C-J Chao. "Ginseng extract and ginsenoside Rb1 attenuate carbon tetrachloride-induced liver fibrosis in rats", BMC Complementary and Alternative Medicine, 2014

Publication

<1 %

27

Zamara, E.. "Prevention of severe toxic liver injury and oxidative stress in MCP-1-deficient mice", Journal of Hepatology, 200702

Publication

<1 %

28

advbiores.net

Internet Source

<1 %

29

biointerfaceresearch.com

Internet Source

<1 %

30

Cheng Yang, Li'e Meng, Yuan Tian, Tao Huang, Yuanying Li. "Cytotoxicity study of a novel implant material modified by microarc oxidation", Journal of Huazhong University of Science and Technology, 2006

Publication

<1 %

31

Sayan Biswas, Amit Kar, Nanaocha Sharma, Pallab K. Haldar, Pulok K. Mukherjee. " Synergistic effect of ursolic acid and piperine in CCl induced hepatotoxicity ", Annals of Medicine, 2021

Publication

<1 %

32

Tonny Maigoda, Judiono Judiono, Dicki Bakhtiar Purkon, Ayu Nala El Muna Haerussana, Gurid Pramintarto Eko Mulyo. "Evaluation of Peronema canescens Leaves Extract: Fourier Transform Infrared Analysis, Total Phenolic and Flavonoid Content, Antioxidant Capacity, and Radical Scavenger Activity", Open Access Macedonian Journal of Medical Sciences, 2022

Publication

<1 %

33

journal.ubb.ac.id

Internet Source

<1 %

34

lipidworld.biomedcentral.com

Internet Source

<1 %

35

microbiologyjournal.org

Internet Source

<1 %

36

www.koreascience.or.kr

Internet Source

<1 %

37

www.medigraphic.com

Internet Source

<1 %

38

Injac, R.. "Potential hepatoprotective effects of fulleranol C⁶⁰(OH)₂₄ in doxorubicin-induced hepatotoxicity in rats with mammary carcinomas", *Biomaterials*, 200808

Publication

<1 %

39

Luiz Francisco Wemmenson Gonçalves Moura, João Xavier da Silva Neto, Tiago Deiveson Pereira Lopes, Stephen Rathinaraj Benjamin et al. "Ethnobotanic, phytochemical uses and ethnopharmacological profile of genus *Cnidoscolus* spp. (Euphorbiaceae): A comprehensive overview", *Biomedicine & Pharmacotherapy*, 2019

Publication

<1 %

40

Nida Nayyar Farshori. "Hepatoprotective effect of *Trigonella foenum graecum* against

<1 %

ethanol-induced cell death in human liver cells
(HepG2 and Huh7)", Molecular Biology
Reports, 2022

Publication

41

Ode, O.J.. "The anti-snake venom activities of the methanolic extract of the bulb of *Crinum jagus* (Amaryllidaceae)", *Toxicon*, 20060901

Publication

<1 %

42

Roodabeh Bahramsoltani, Mohammad Hosein Farzaei, Soraya Sajadimajd, Amin Iranpanah et al. "In vitro and in vivo antidiabetic activity of *Tamarix stricta* Boiss.: Role of autophagy", *Journal of Ethnopharmacology*, 2020

Publication

<1 %

43

Trinh T. Tran, Pamela Groben, David S. Pisetsky. "The release of DNA into the plasma of mice following hepatic cell death by apoptosis and necrosis", *Biomarkers*, 2008

Publication

<1 %

44

api-ir.unilag.edu.ng

Internet Source

<1 %

45

ijcrr.com

Internet Source

<1 %

46

jrespharm.com

Internet Source

<1 %

47

repub.eur.nl

Internet Source

<1 %

48

vdoc.pub

Internet Source

<1 %

49

www.ijppsjournal.com

Internet Source

<1 %

50

www.notulaebiologicae.ro

Internet Source

<1 %

51

Oluwatobi T. Somade, Oluseyi A. Akinloye,
Regina N. Ugbaja, Mopelola A. Idowu.

"Cnidoscolus aconitifolius leaf extract exhibits comparable ameliorative potentials with ascorbate in dimethylnitrosamine-induced bone marrow clastogenicity and hepatotoxicity", Clinical Nutrition Experimental, 2020

Publication

<1 %

52

Ozolua, R.I.. "Increased superoxide dismutase and Na⁺, K⁺-ATPase activities in aortic strips from potassium-adapted rats: implication for altered vascular reactivity", Comparative Biochemistry and Physiology, Part C, 200305

Publication

<1 %

53

Temidayo Olutayo Omobowale, Ademola Adetokunbo Oyagbemi, Uchechukwu Enwiwe Ajufu, Olumuyima Abiola Adejumobi et al.
"Ameliorative Effect of Gallic Acid in Doxorubicin-Induced Hepatotoxicity in Wistar

<1 %

Rats Through Antioxidant Defense System",
Journal of Dietary Supplements, 2017

Publication

54

Safwat M. S. Abo-Qotb, Ahmed M. M. Hassanein, Samar Y. Desoukey, Amira S. Wanas, Heba M. Tawfik, Mohammed A. A. Orabi. " In vivo anti-inflammatory and hepatoprotective activities of (Forssk.) aerial parts in relation to its phytomolecules ", Natural Product Research, 2020

Publication

<1 %

55

Yong-Ping Zheng, Xian-Yang Zhong, Yu-Shu Huang, Can-Bin Zheng. "HCBP6 Is Involved in the Development of Hepatic Steatosis Induced by High-Fat Diet and CCL4 in Rats", Annals of Hepatology, 2018

Publication

<1 %

56

Yoshiji Ohta. "Melatonin prevents disruption of hepatic reactive oxygen species metabolism in rats treated with carbon tetrachloride", Journal of Pineal Research, 1/2004

Publication

<1 %

Exclude quotes Off

Exclude matches Off

Exclude bibliography On

Effect of Cnidocolus aconitifolius Extract on Rat Liver Injury Induced with Carbon Tetrachloride (CCl4)

GRADEMARK REPORT

FINAL GRADE

/0

GENERAL COMMENTS

Instructor

PAGE 1

PAGE 2

PAGE 3

PAGE 4

PAGE 5
